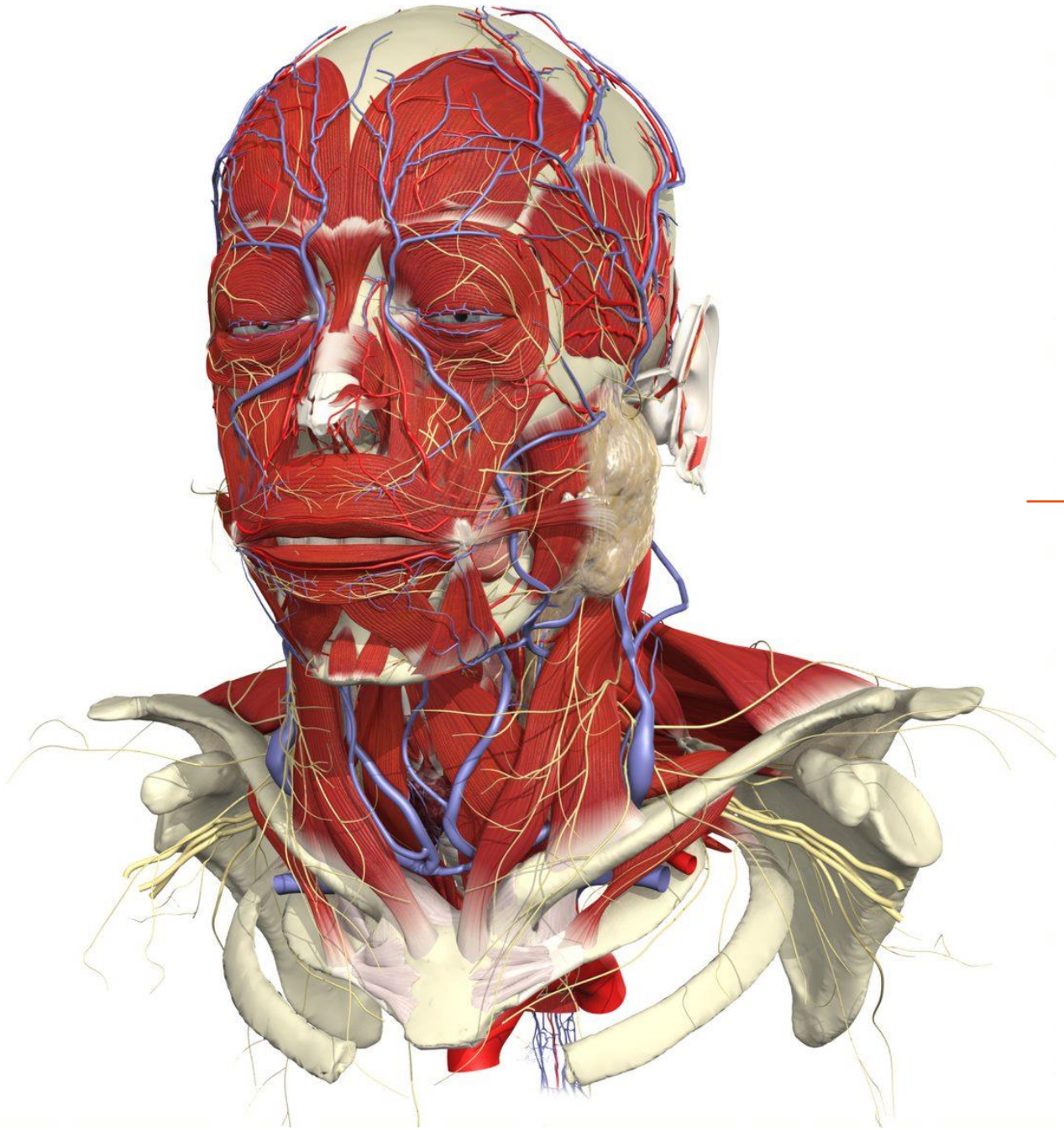

PRIMAL PICTURES

The World’s best digital human anatomy & physiology content for education

Who is Primal?

- 30+ years of experience
- Only model built from the ground up, using real scan data
- Supporting over 1,500 institutions globally
- Used in Practice & Healthcare environments across the World (including the NHS and US Veterans Administration)
- Enable commercial organisations to communicate internally and externally more credibly and drive differentiation
- Our users dictate our strategy!

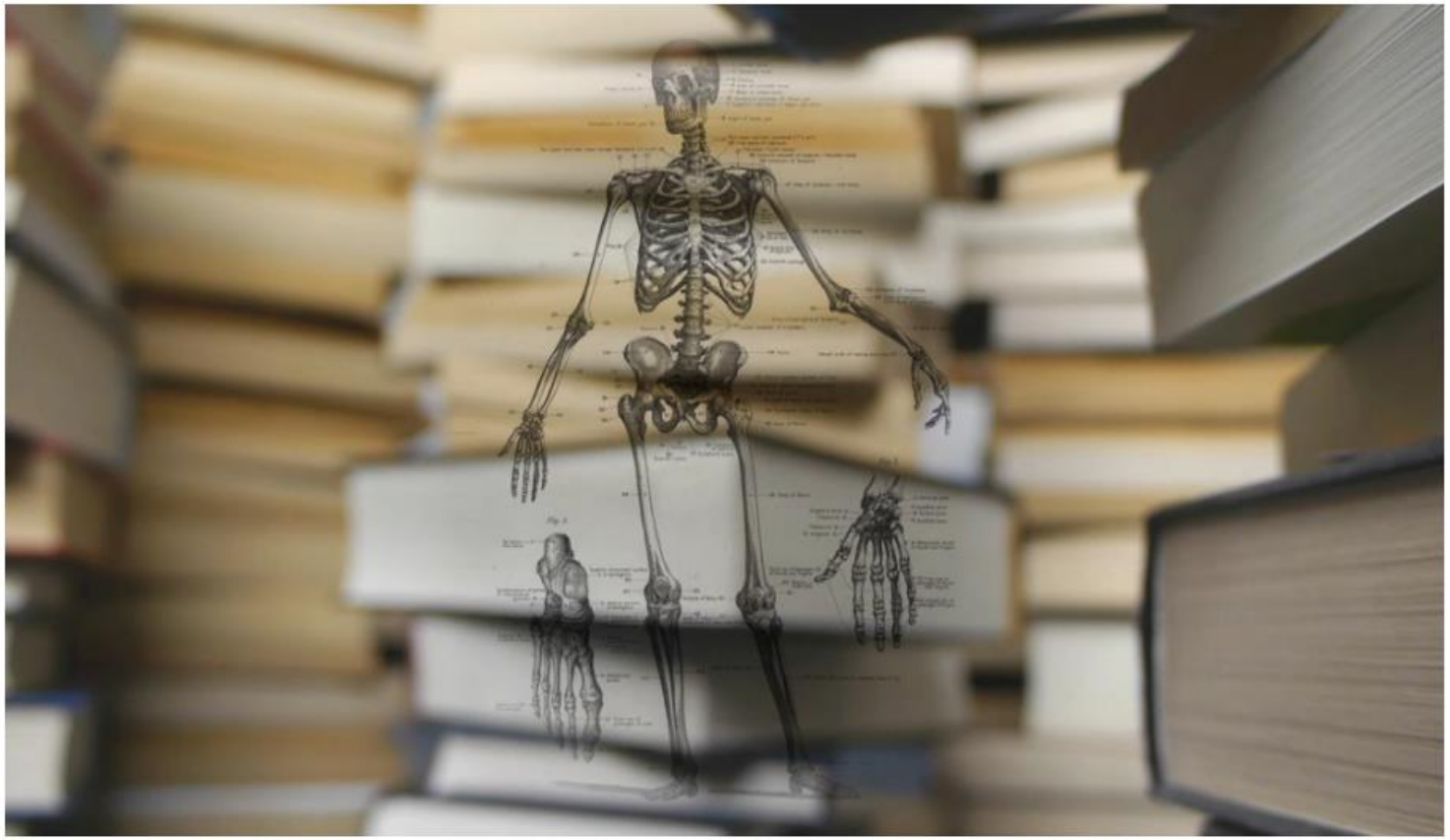

The Primal Approach

"Since its (Primal Pictures) addition, exam scores have increased by nearly 12% over previous years."

Justin Miller – Professor – Carthage College, Wisconsin

Enable Faculty

Empower Students

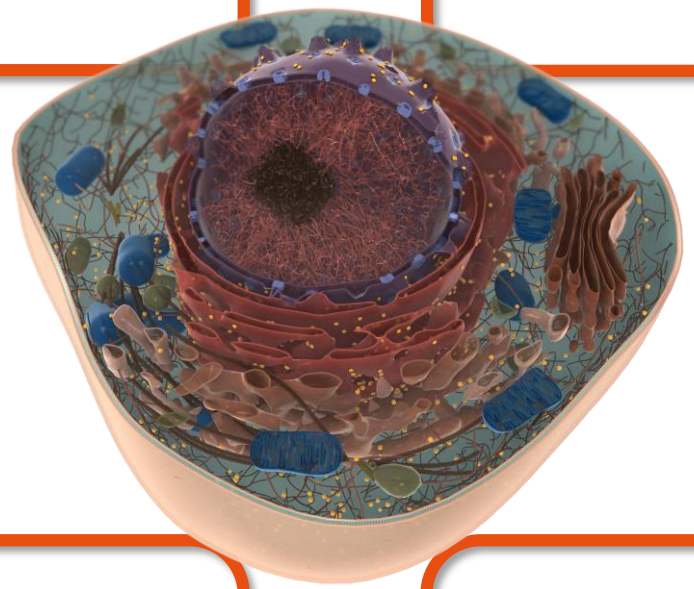

Diverse Learning Opportunities

Accessibility

Tailored solutions for superior learning

For a tailored solution to supporting anatomy learning at every stage of Medical School education, Primal has the answer.

Primal Pictures combines unique functionality with superior anatomy content, ideal for faculty and students alike.

Primal Pictures' anatomy solutions are specifically designed to support and enhance the learning process every step of the way.

GROSS ANATOMY
Become familiar with anatomy with a step- by-step intro in Anatomy & Physiology

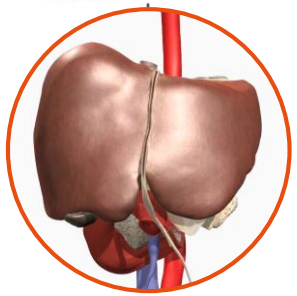

ASSESSMENT
Retain what was learned with Quizzes and PALMS (Perceptual Adaptive Learning Modules)

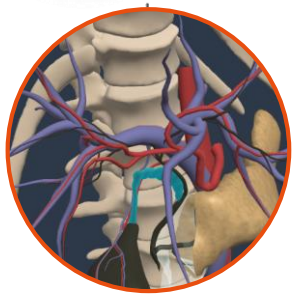

DISSECTION
Understand the anatomy in context and prepare for the cadaver lab with Real-time

FUNCTION
Go deeper into microanatomy or anatomy function using Anatomy and Physiology

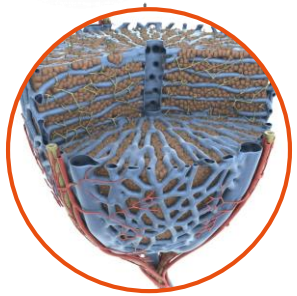

IMAGING
Apply knowledge to imaging cross sectional anatomy using Cross-sectional anatomy of the trunk

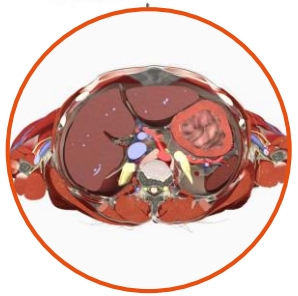

CLINICAL
Understand the pathologies that may affect that anatomy using Disease and Conditions movies

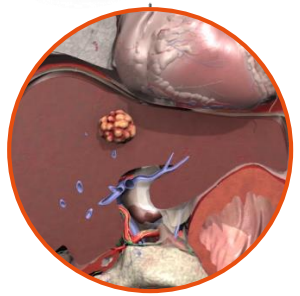

Flexibility and Integration

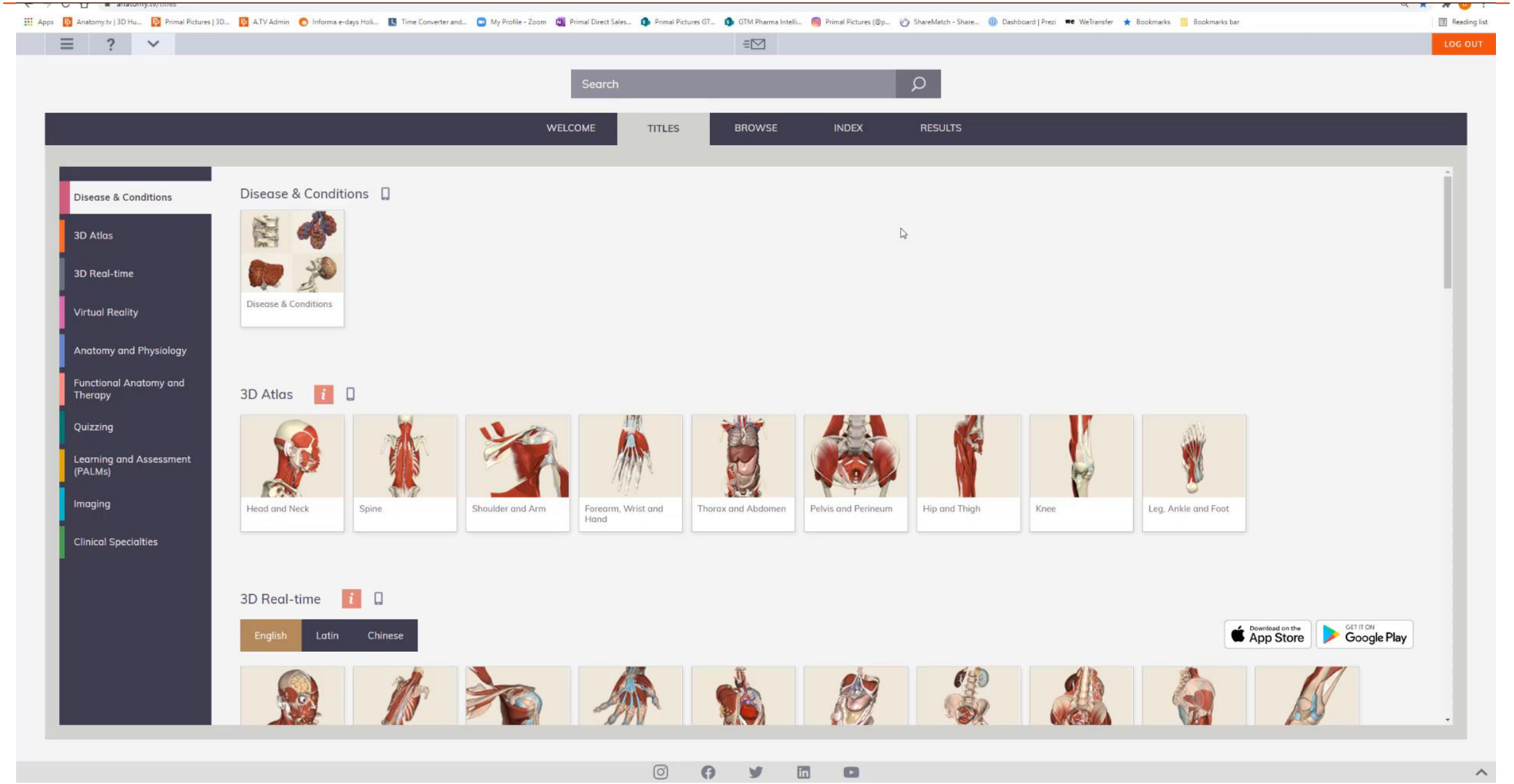

Primal VR

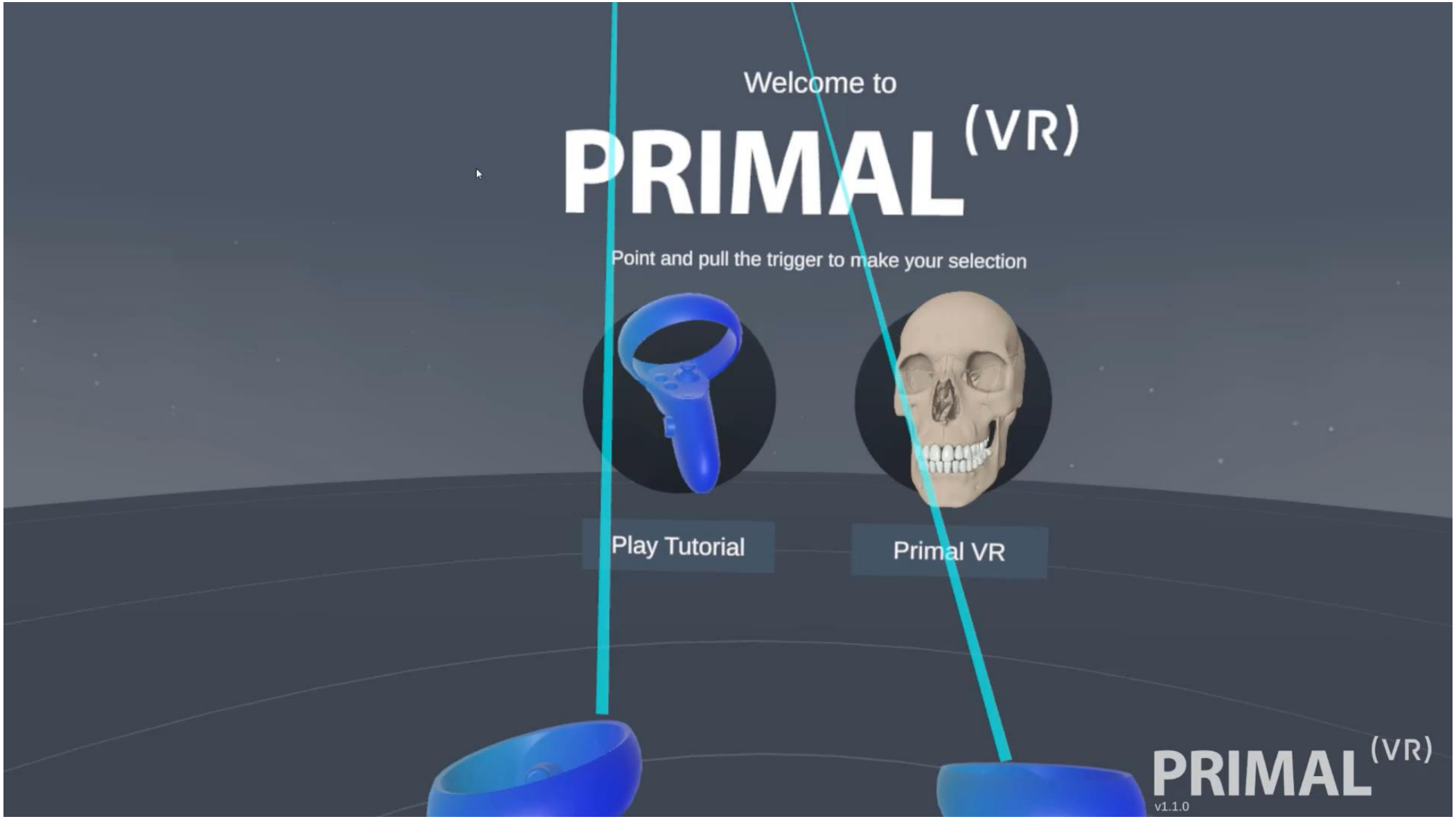
Welcome to
PRIMAL (VR)
Point and pull the trigger to make your selection
Play Tutorial
Primal VR
PRIMAL (VR)
v1.1.0

Real-time Functional Anatomy

Demonstration

Real-time Functional Anatomy

Why is RTFA valuable?

Educational requirement

Authoritative content

Improved efficiency

Heightened understanding

Positive outcomes

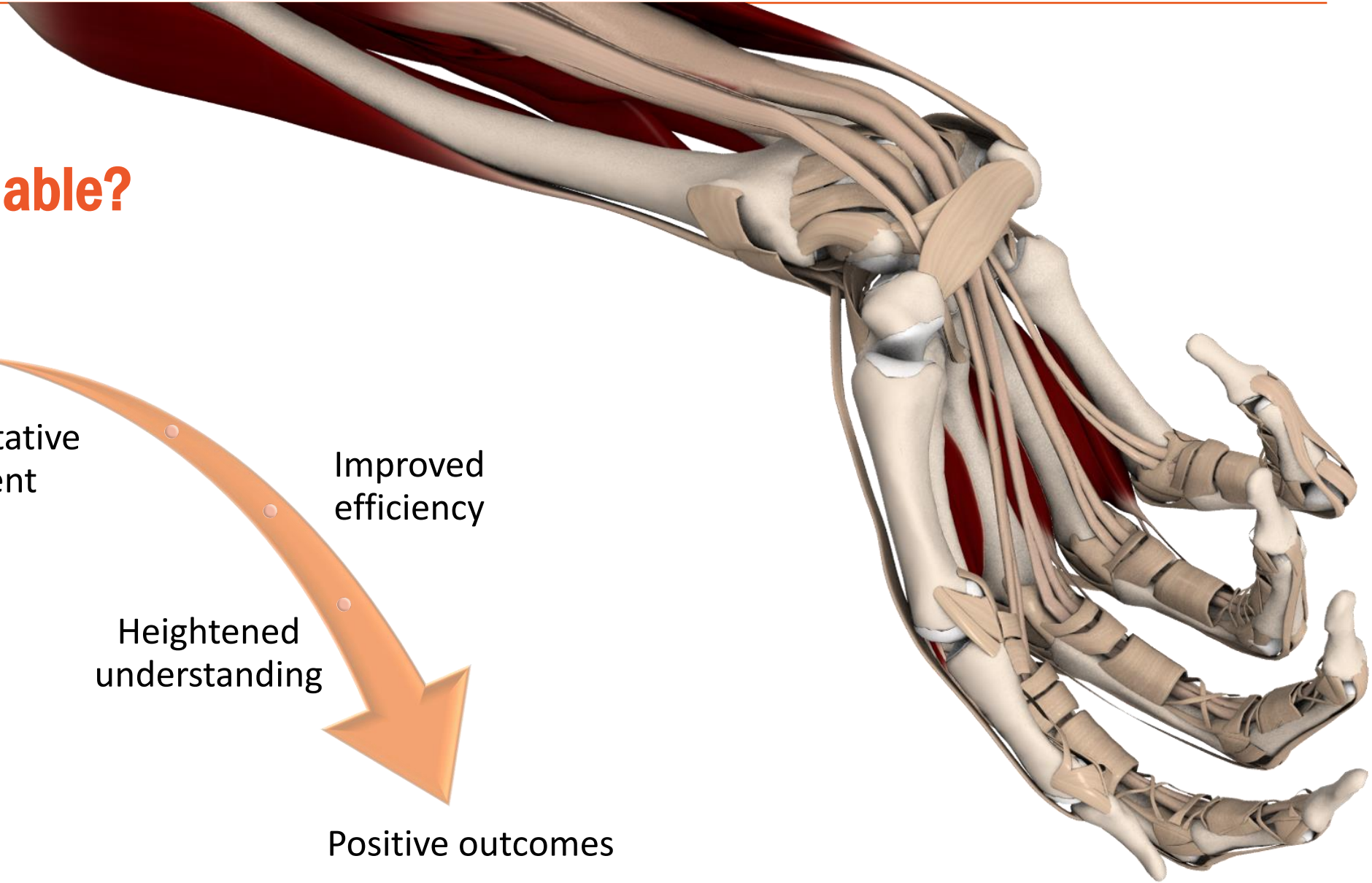

Primal's Anatomy Learning Outcomes for Medicine

Head and neck

Overview

Medical graduates should be able to demonstrate the position of the palpable and imaging landmarks of the major bones of the skull, including the frontal, parietal, temporal, occipital, maxilla, mandible, nasal, sphenoid, zygoma and ethmoid bones. Demonstrate the palpable position of the hyoid bone, thyroid and cricoid cartilages, lateral mass of the atlas and the spine of C7. Demonstrate the major sutural joints of the skull and describe the fontanelles of the neonatal skull.

6. Describe the boundaries, walls and floors of the cranial fossae.
7. Describe the relationships between the structures of the brain and the anterior, middle and posterior cranial fossae.
8. Identify the major foramina of the skull, both internally and externally, and list the structure(s) that each transmits.
9. Describe the arrangement of the pia, arachnoid and dura mater within the cranial cavity and in relation to the brain. Describe the reflections of the dura mater and the formation of the venous sinuses.
10. Describe the anatomy of the dural venous sinuses. Explain the entrance of cerebral veins into the superior sagittal sinus in relation to subdural haemorrhage. Explain how connections between sinuses and extracranial veins may permit intracranial infection.
11. Describe the anatomy of the individual layers of the scalp. Describe the significance of its blood supply, particularly in relation to laceration injuries.
12. Describe the main muscles of the face and summarise their nerve supply and the consequences of injury to their nerve supply.
13. Describe the anatomy of the eyelid, conjunctiva and lacrimal gland. Explain their importance for the maintenance of corneal integrity.
14. Describe the boundaries of the orbit, the globe of the eye and the location, actions and nerve supply of the intrinsic and extraocular muscles. Explain the consequences of injury to their nerve supply.
15. Describe the bones of the nasal cavity, in particular the major features of the lateral wall of the nasal cavity. Describe the arteries that supply the lateral wall and nasal septum in relation to epistaxis.
16. Name the paranasal sinuses. Describe their relationship to the nasal cavity and their sites of drainage through its lateral wall. Explain their innervation in relation to referred pain.
17. Describe the intracranial and intrapetrous course of the facial nerve and the relationships of its major branches to the middle ear in relation to damage of the nerve within the facial canal.
18. Describe the anatomy of the temporomandibular joint. Explain the movements that occur during mastication and describe the muscles involved and their innervation.
19. Describe the course and major branches of the maxillary artery, including the course and intracranial relations of the middle meningeal artery and its significance in extradural haemorrhage.
20. Describe the anatomy of the sensory and motor components of the trigeminal nerve, including how their integrity is tested clinically.

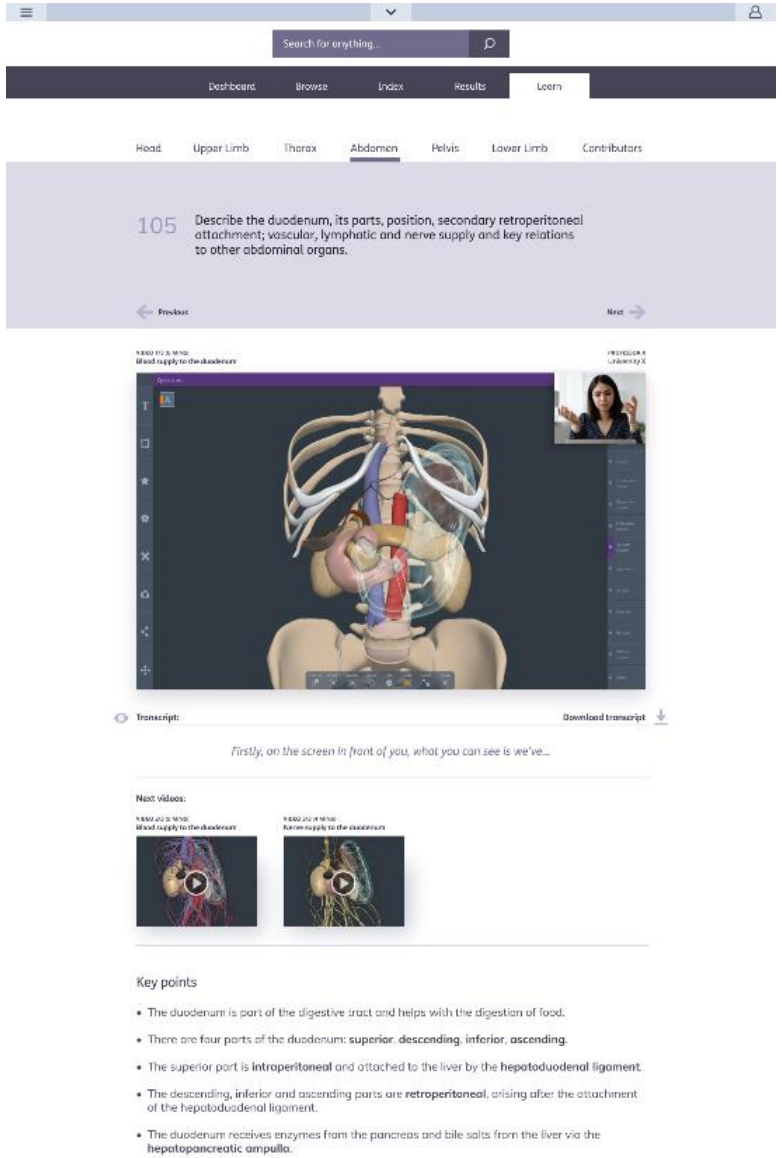

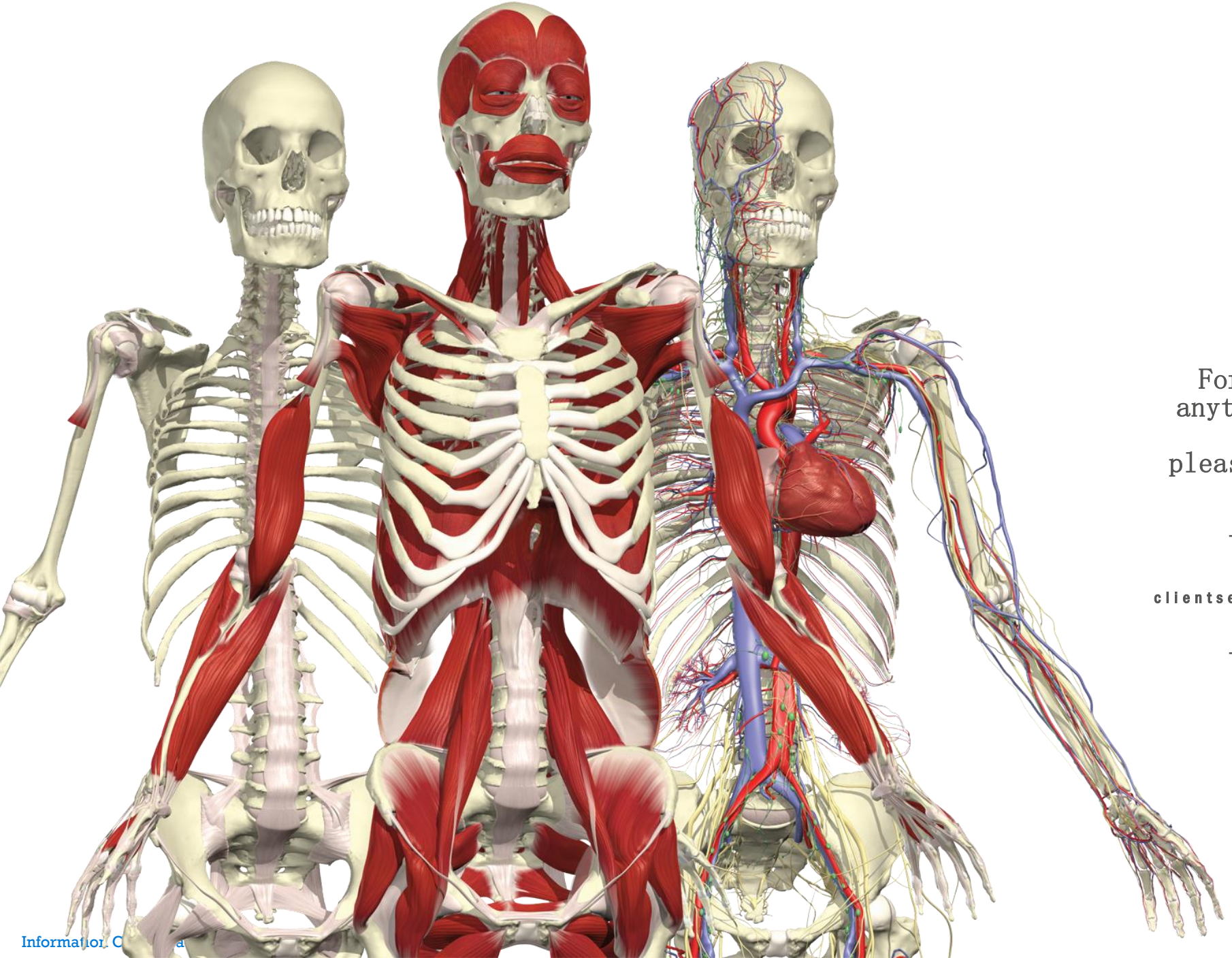

THANK YOU

For more information on anything related to Primal
–
please contact your Account Manager

clientservices@primalpictures.com